Frontal Fibrosing Alopecia

ICD-10 Coordination and Maintenance March 2023 Meeting

Speaker: Maria Hordinsky, MD



Itisha S Jefferson

Jessica Brown-Korsah

Morinola Shobajo

James Pathoulas, MD

Amy McMichael, MD

Maria Hordinsky, MD

SAF scarring alopecia.org
SCARRING ALOPECIA FOUNDATION

AAD American Academy of Dermatology Association

Frontal Fibrosing Alopecia (FFA)

- Inflammation around stem cells of hair follicles causes scarring and permanent hair loss along the frontotemporal hairline.
- First described in 1994, exponential increase in cases, now considered an epidemic, frequently seen in dermatology clinics.[1]
- Can cause decreased quality of life and psychosocial distress from disfigurement and scalp symptoms[2]
- Poor understanding of etiology, few treatment options[3,4]
- FFA is unlike other scarring hair disorders but does not have a separate ICD-10-CM code, preventing research that could improve patient care

Courtesy of Dr Isabella Doche - University of São Paulo (Brasil)

Esteban-Lucía L, Molina-Ruiz AM, Requena L. Update on Frontal Fibrosing Alopecia. Actas Dermo-Sifiliográficas. 2017;108(4):293-304.

Background & Epidemiology

SAF

- New poorly understood disorder affecting many worldwide, inadequate population-level research in US due to lack of an ICD-10-CM code[5]
- Shares histologic features with scarring alopecia lichen planopilaris and was thought to be a variant, but clinical and pathological differences now identified[6,7]
- Undetermined pathophysiology: potential environmental, hormonal, and genetic factors contributory[3,6-8]
- Initially described in postmenopausal women, now seen in both premenopausal women and men[1,9,10]
- Average age of onset between 56-66 but now presenting in younger adults[4,5,9]

Clinical Features

- Patients can experience **debilitating** itch, burning, pain, “skin-crawling” sensation, redness, prominent temporal veins, central scalp depression, and loss of eyebrows, eyelashes, other facial, and body hair[1,5,9,10]

Tziotzios C, Stefanato CM, Fenton DA, Simpson MA, McGrath JA. Frontal fibrosing alopecia: reflections and hypotheses on aetiology and pathogenesis. Exp Dermatol. 2016 Nov;25(11):847-852.

Clinical Findings

Prominent temporal veins

Pirmez R, et al.. Successful Treatment of Facial Papules in FFA with Oral Isotretinoin. *Skin App Disord*. 2017;3(2):111-113.

Facial papules

Courtesy of Dr Isabella Doche - University of São Paulo (Brasil)

Eyebrow and eyelash loss

Melo DF, et al. Ten clinical clues for the diagnosis of frontal fibrosing alopecia. *Indian J Dermatol Venereol Leprol*. 2019;85(5):559-564.

Lichen planopilaris is different than FFA

Courtesy Dr. Maryanne M. Senna, Lahey Hospital & Medical Center - Department of Dermatology, Burlington, MA, USA.

Melo DF, de Mattos Barreto T, de Souza Albernaz E, Haddad NC, Tortelly VD. Ten clinical clues for the diagnosis of frontal fibrosing alopecia. *Indian J Dermatol Venereol Leprol*. 2019;85(5):559-564.

Diagnosis

- Clinical and histopathological

Esteban-Lucía L, Molina-Ruiz AM, Requena L. Update on Frontal Fibrosing Alopecia. Actas Dermo-Sifiliográficas. 2017;108(4):293-304.

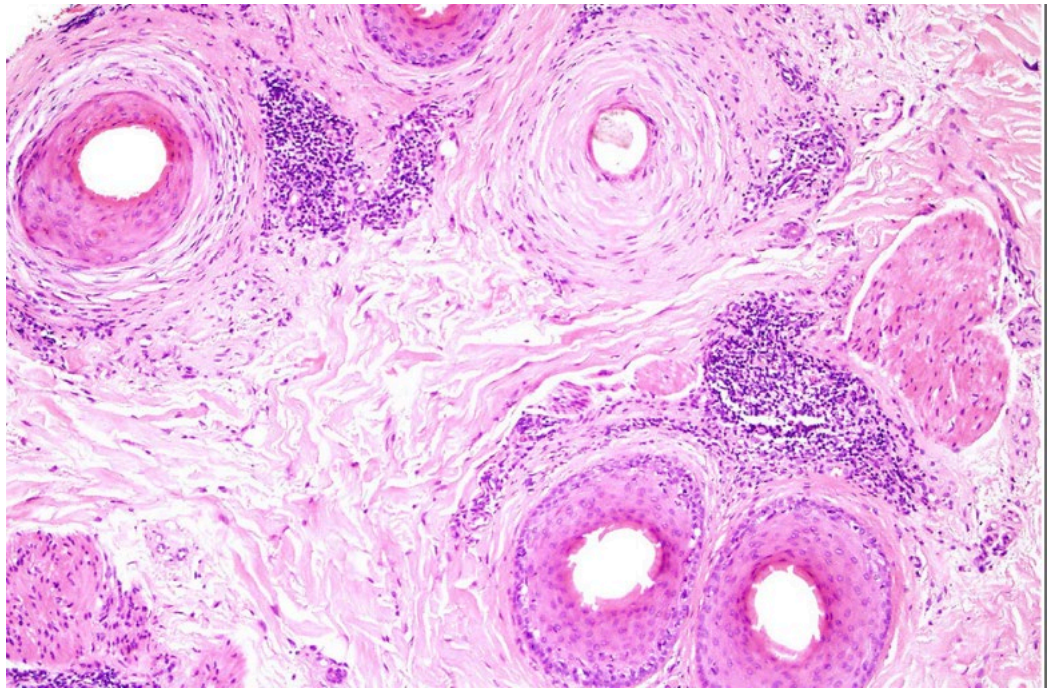

Tziotzios C, Stefanato CM, Fenton DA, Simpson MA, McGrath JA. Frontal fibrosing alopecia: reflections and hypotheses on aetiology and pathogenesis. Exp Dermatol. 2016 Nov;25(11):847-852.

Treatment

- Current treatment aimed at reducing inflammation and controlling scalp symptoms:
  - Topical steroids, calcineurin inhibitors, and gabapentin
  - Intralesional corticosteroids
  - Phototherapy
  - Antimalarials
  - Retinoids
  - JAK inhibitors are an emerging treatment

- Limited efficacy of current therapies prevent disease control for some patients

Current ICD-10-CM Codes

SAF

- Disorders of skin appendages (L60-L75)
  - Cicatricial alopecia (L66)
    - Pseudopelade(L66.0)
    - **Lichen planopilaris (L66.1)**
    - Folliculitis decalvans (L66.2)
    - Perifolliculitis capitis abscedens (L66.3)
    - Folliculitis ulerythematosa reticulata(L66.4)
    - **Other cicatricial alopecia (L66.8)**
    - Cicatricial alopecia, unspecified (L66.9)

Need for distinct FFA code

- Lichen planopilaris ≠ FFA [1-3]
- Incidence increasing globally[2]
- Foundation for basic epidemiologic studies in U.S.
- Monitor adherence to clinical management guidelines
- Track and improve patient care outcomes
- Potential equity implications[4,5]

Support


AMERICAN ACADEMY OF DERMATOLOGY
AAD
1938

SAF
scarring alopecia.org
SCARRING ALOPECIA FOUNDATION

References

1. Kossard S. Postmenopausal frontal fibrosing alopecia. Scarring alopecia in a pattern distribution. Archives of Dermatology. 1994;130(6):770-774. doi:10.1001/archderm.130.6.770
2. Doche I, Romiti R, Rivitti-Machado MC, Gorbatenko-Roth K, Freese RL, Hordinsky MK. Quality-of-life impairment is not related to disease activity in lichen planopilaris and frontal fibrosing alopecia. Results of a preliminary cross-sectional study. J Eur Acad Dermatol Venereol. 2022 Apr;36(4):e288-e290. doi: 10.1111/jdv.17798. Epub 2021 Nov 18. PMID: 34753220.
3. Prasad S, Marks DH, Burns LJ, et al. Patch testing and contact allergen avoidance in patients with lichen planopilaris and/or frontal fibrosing alopecia: A cohort study. Journal of the American Academy of Dermatology. Published online January 2020:S0190962220300773. doi:10.1016/j.jaad.2020.01.026
4. Maghfour J, Ceresnie M, Olson J, Lim HW. The Association between Frontal Fibrosing Alopecia, Sunscreen, and Moisturizers: A Systematic Review with a Meta-Analysis. Journal of the American Academy of Dermatology. Published online January 2022:S0190962222000834. doi:10.1016/j.jaad.2021.12.058
5. McMichael A, Hordinsky M. Hair and Scalp Disorders Medical, Surgical, and Cosmetic Treatments, Second Edition. 2nd ed. CRC Press; 2018.
6. Doche I, Wilcox GL, Ericson M, et al. Evidence for neurogenic inflammation in lichen planopilaris and frontal fibrosing alopecia pathogenic mechanism. Exp Dermatol. 2020;29(3):282-285. doi:10.1111/exd.13835
7. Harries M, Hardman J, Chaudhry I, Poblet E, Paus R. Profiling the human hair follicle immune system in lichen planopilaris and frontal fibrosing alopecia: can macrophage polarization differentiate these two conditions microscopically? Br J Dermatol. 2020;183(3):537-547. doi:10.1111/bjd.18854
8. Tziotzios C, Petridis C, Dand N, et al. Genome-wide association study in frontal fibrosing alopecia identifies four susceptibility loci including HLA-B*07:02. Nat Commun. 2019;10(1):1150. doi:10.1038/s41467-019-09117-w
9. McSweeney SM, Christou EAA, Dand N, et al. Frontal fibrosing alopecia: a descriptive cross-sectional study of 711 female cases from the U.K. Br J Dermatol. Published online July 11, 2020:bjd.19399. doi:10.1111/bjd.19399
10. Pathoulas JT, Flanagan KE, Walker CJ, Collins MS, Ali S, Pupo Wiss IM, Cotsarelis G, Milbar H, Huang K, Mostaghimi A, Scott D, Han JJ, Lee KJ, Hordinsky MK, Farah RS, Bellefeuille G, Raymond O, Bergfeld W, Ranasinghe G, Shapiro J, Lo Sicco KI, Gutierrez D, Ko J, Mirmirani P, Mesinkovska N, Yale KL, Goldberg LJ, Tosti A, Gwillim EC, Goh C, Senna MM. A multicenter descriptive analysis of 270 men with frontal fibrosing alopecia and lichen planopilaris in the United States. J Am Acad Dermatol. 2022 Nov 15:S0190-9622(22)03005-5.