Anal Fistula Classification

ICD-10 Coordination and Maintenance Committee meeting
March 8-9, 2022

Biography: Dr. David Schwartz

- Professor of Medicine in the Division of Gastroenterology, Hepatology, and Nutrition at Vanderbilt University in Nashville, Tennessee
- Founded and currently serves as the Director of the Inflammatory Bowel Disease (IBD) Center at Vanderbilt University Medical Center
- Postgraduate training at the Mayo Clinic in Rochester, Minnesota: fellowship in Gastroenterology and Hepatology, and advanced training in IBD and Endoscopic Ultrasound
- Fellow of the American College of Gastroenterology and the American Gastroenterological Association
- Editorial experiences include serving as a Section Editor for the IBD journal (2006-2014), Associate Editor for Gastrointestinal Endoscopy (2014-1015), and currently serves as the Select Summary Editor for Gastroenterology
- Research has focused on clinical trials for IBD, imaging of IBD, the multidisciplinary care of the IBD patient, and the treatment of perianal Crohn's disease
- Paid consultant for, and presenting on behalf of, Takeda (applicant)

Today's Agenda

1	Overview of Anal Fistulas
2	Current Diagnosis and Management of Anal Fistulas
3	Rationale for New ICD-10 Codes

Crohn's disease (CD) is a type of chronic inflammatory bowel disease

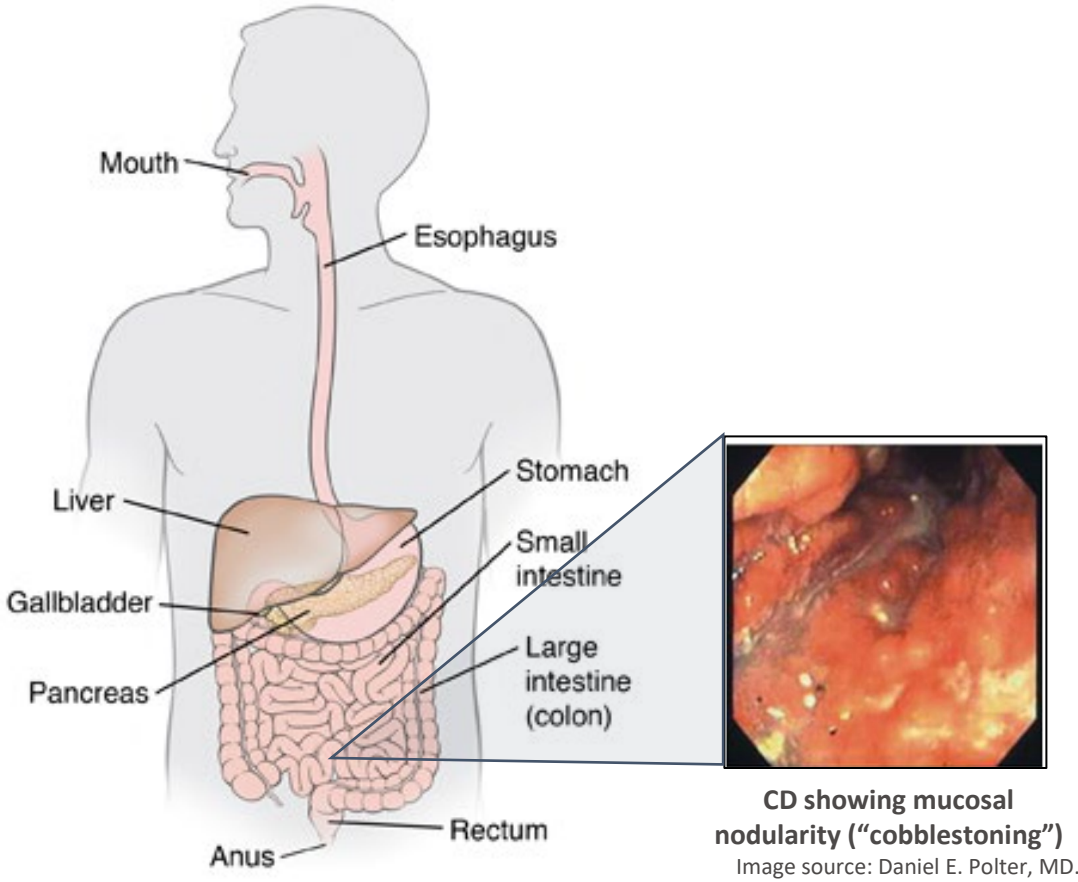

CD showing mucosal nodularity ("cobblestoning")
Image source: Daniel E. Polter, MD.
In: Kefalas CH. *Proc (Bayl Univ Med Cent)*. 2003; 16(2):147-151. With permission.

- CD can affect any part of the GI tract from the mouth to the perianal area
- Features of CD include skip lesions, transmural involvement, and granulomas
- Over time, inflammation may extend through the layers of the bowel (through the intestinal wall from the mucosa to serosa)
- CD often presents with abdominal pain and perianal disease
  - Perianal disease may include anal fistula

CD, Crohn's disease; GI, gastrointestinal.

John Hopkins Medicine. Crohn's disease: introduction. https://www.hopkinsmedicine.org/gastroenterology_hepatology/_pdfs/small_large_intestine/crohns_disease.pdf. Accessed March 11, 2020.

Anal fistulas and abscesses are the most common manifestations of perianal Crohn's disease (CD)

Proportion of patients with perianal CD based on type of perianal lesions

Range of onset of perianal symptoms: 18 years prior to diagnosis – 33 years after diagnosis

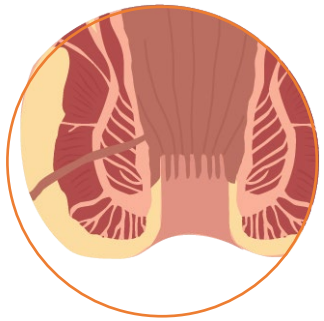

Anal fistula **42%**

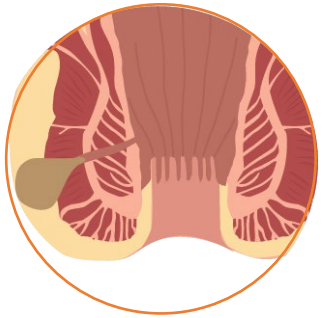

Perianal abscess **42%**

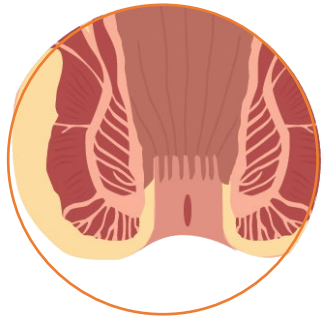

Anal fissure/ulcer **33%**

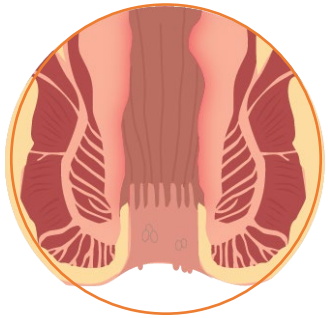

Skin tag **11%**

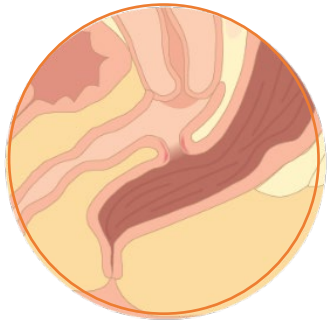

Rectovaginal fistula **8%**

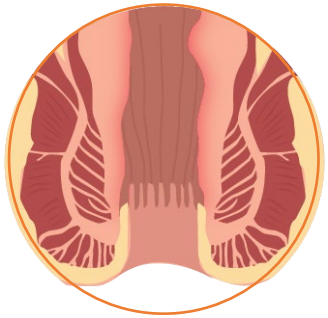

Anorectal stricture **7%**

- In a population-based cohort study, 44.1% of patients already had one or more clinical features of perianal involvement within 6 months after diagnosis of CD

CD, Crohn's disease.

Eglinton TW, et al. *Dis Colon Rectum*. 2012;55:773-777.

Anal fistulas have an internal opening in the anal canal/rectum and an external opening in the skin near the anus[1]

- Anal fistulas in CD are thought to arise from inflamed or infected anal glands and/or penetration of fissures or ulcers in the mucosa lining the rectum or anal canal.[1]
- Importantly, cryptoglandular fistulas differ from anal fistulas in CD as they arise from inflamed anal glands that are situated in the intersphincteric space. [2] A communication forms between an opening at the level of the dentate line and one in the perianal region.

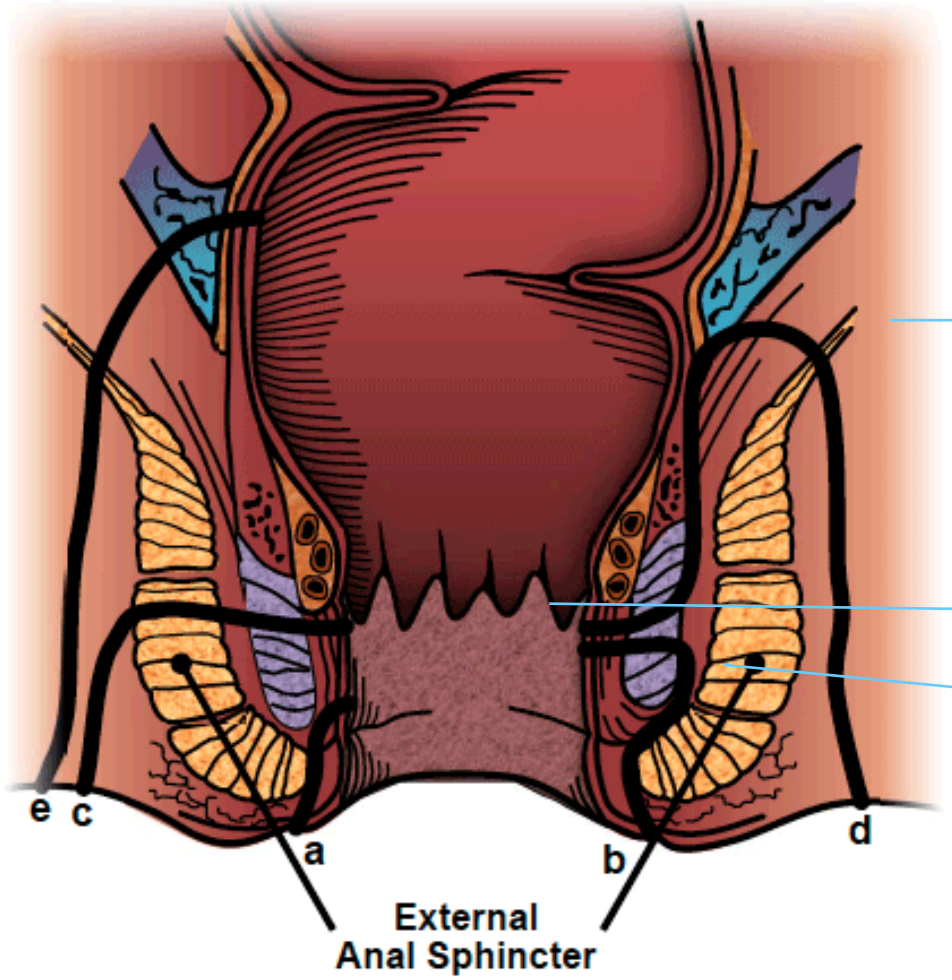

Fistula type:
a. Superficial
b. Intersphincteric
c. Transsphincteric
d. Suprasphincteric
e. Extrasphincteric

Levator Ani

Dentate line

Internal anal sphincter

Figure 1 Adapted from https://fascrs.org/patients/diseases-and-conditions/a-z/abscess-and-fistula-expanded-information

CD, Crohn's disease

1. Sandborn I, et al. *Gastroenterology.* 2003;125:1508-1530. 2. Parks. Br J Surg 1976;63:1-12.

Adequate classification of fistulas is crucial for choosing optimal medical and/or surgical treatment[1]

There is no consensus for classifying perianal fistulas in CD, but AGA (most common) or Parks classification may be used clinically[1,2]

AGA classification[2]

Simple fistula[3]

- Low-tract[a]
- Single external opening
- No abscess, rectovaginal fistula, or anorectal stricture

Complex fistula[3]

- High-tract (high intersphincteric or high transsphincteric or extrasphincteric or suprasphincteric origin of the fistula tract)[a]
- Multiple external openings
- Presence of perianal abscess, rectovaginal fistula, or anorectal stricture, and may be associated with presence of active rectal disease at endoscopy

Parks classification[1-4]

Parks classification uses external sphincter as the reference point[1,4]

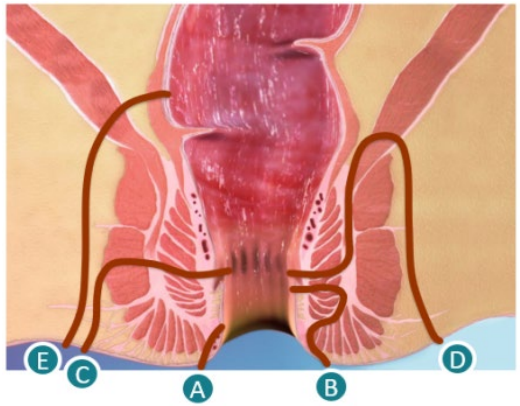

A. Superficial
B. Intersphincteric
C. Transsphincteric
D. Suprasphincteric
E. Extrasphincteric

Complex fistulas are less likely to heal after treatment than simple fistulas, and on average require a greater number of and more extensive treatments.[5]

[a]Perianal fistulas are commonly referred to as high or low relative to either the lower third of the external anal sphincter[3] or to the dentate line.[1,3]

AGA, American Gastroenterological Association; CD, Crohn's disease.

1. Parks AG, et al. *Br J Surg*. 1976;63(1):1-12. 2. Marzo M, et al. *World J Gastroenterol*. 2015;21(5):1394-1403. 3. Sandborn WJ, et al. *Gastroenterology*. 2003;125(5):1508-1530. 4. Vermeire S, et al. *Dig Liver Dis*. 2007;39(10):959-962. 5. Bell SJ, et al. *Aliment Pharmacol Ther*. 2003 May 1;17(9):1145-51.

The current treatment paradigm differs for simple vs. complex fistulas

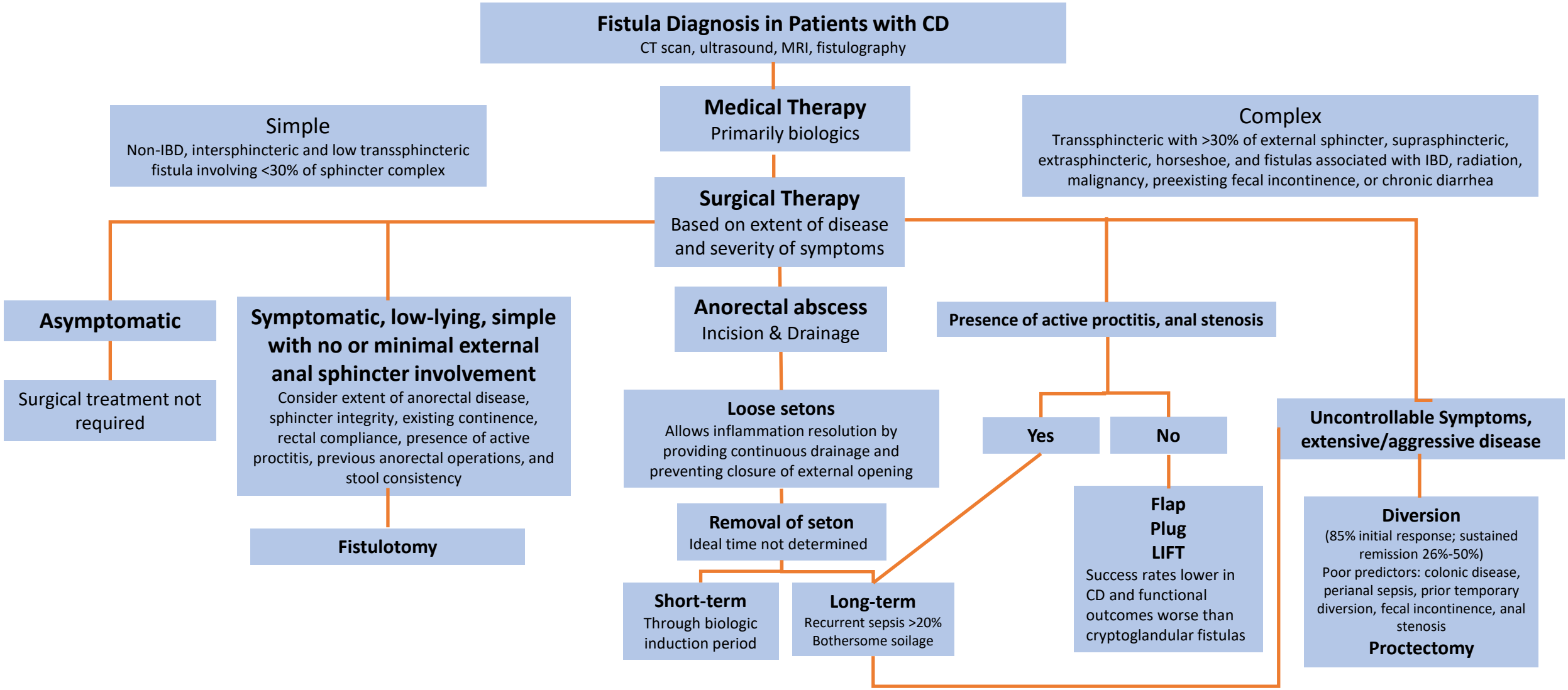

ASCRS, American Society of Colon and Rectal Surgeons; CD, Crohn's disease; CT, computed tomography; FLAP, endoanal advancement flap; IBD, inflammatory bowel disease; LIFT, ligation of the intersphincteric fistula tract; US, United States.

Vogel JD et al. Dis Colon Rectum 2016;59:1117-1133.

Anal fistula recurrence rates have not changed despite advances in treatment options and strategies

A Dutch registry-based study assessed cumulative 5-year anal fistula recurrence rates in patients diagnosed with CD (N=1162) across 3 eras spanning from 1991 through 2011[1]

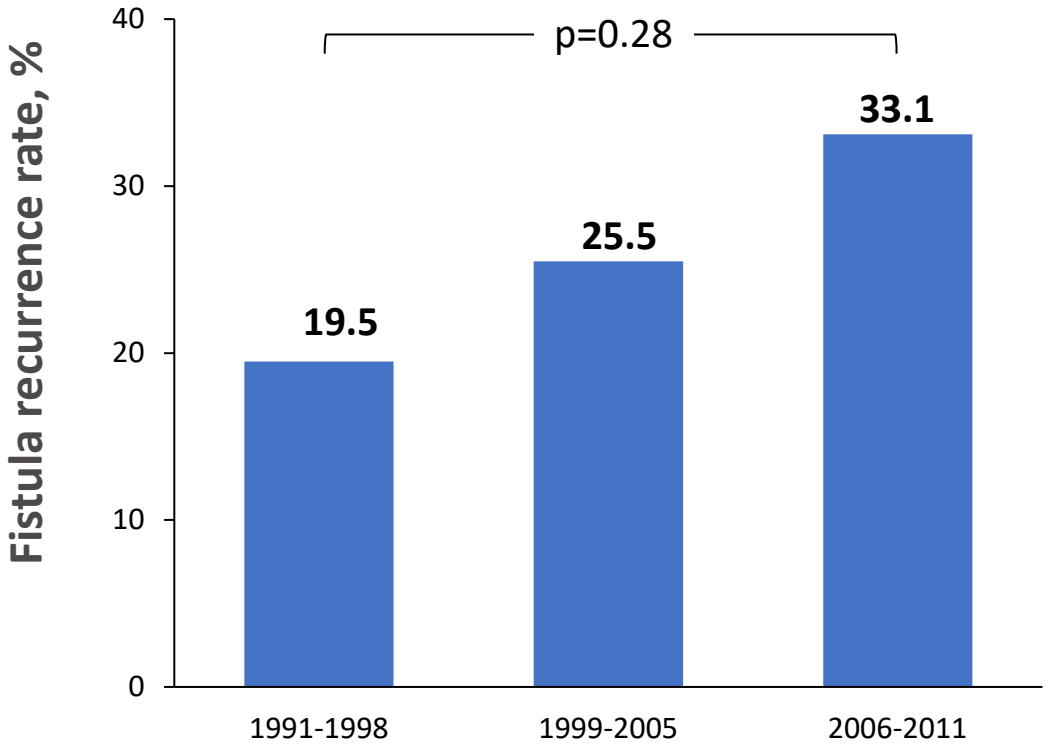

- Fistula recurrence rates increased in spite of all treatment efforts, including the introduction of anti-TNF agents in 1999, though the increase did not reach statistical significance.[1]

CD, Crohn's disease; TNF, tumor necrosis factor.

1. Göttgens KW, et al. *Eur J Gastroenterol Hepatol*. 2017;29(5):595-601

Existing ICD-10 codes do not describe complex anal fistulas and require proxy codes to track the appropriate patient population

ICD-10 Crohn's Disease Coding Details

K50 Crohn's Disease [regional enteritis]
- **K50.0** Crohn's disease of small intestine
  - **K50.01** Crohn's disease of small intestine with complications
    - **K50.013** Crohn's disease of small intestine with fistula
- **K50.1** Crohn's disease of large intestine
  - **K50.11** Crohn's disease of large intestine with complications
    - **K50.113** Crohn's disease of large intestine with fistula
- **K50.8** Crohn's disease of small and large intestine
  - **K50.81** Crohn's disease of small and large intestine with complications
    - **K50.813** Crohn's disease of small and large intestine with fistula
- **K50.9** Crohn's disease, unspecified
  - **K50.91** Crohn's disease, unspecified, with complications
    - **K50.913** Crohn's disease, unspecified, with fistula

*K50 code range describes fistulas specifically in the **intestines and GI tract** which is not appropriate for complex anal fistula given the **differences in anatomical location and treatment paradigm***

ICD-10 Anal Fistula Coding Details

K60 Fissure and fistula of anal and rectal regions
- **K60.0** Acute anal fissure
- **K60.1** Chronic anal fissure
- **K60.2** Anal fissure, unspecified
- **K60.3** Anal fistula
- **K60.4** Rectal fistula
- **K60.5** Anorectal fistula

ICD-10 Rectovaginal Fistula Coding Details

N82 Fistulae involving female genital tract
- **N82.0** Vesicovaginal fistula
- **N82.1** Other female urinary-genital tract fistulae
- **N82.2** Fistula of vagina to small intestine
- **N82.3** Fistula of vagina to large intestine
  - Rectovaginal Fistula
- **N82.4** Other female intestinal-genital tract fistulae
- **N82.5** Female genital track-skin fistulae
- **N82.8** Other female genital tack fistulae
- **N82.9** Female genital track fistula, unspecified

Proposed tabular modifications will ensure better tracking of patients with complex anal fistulas and thereby improve research
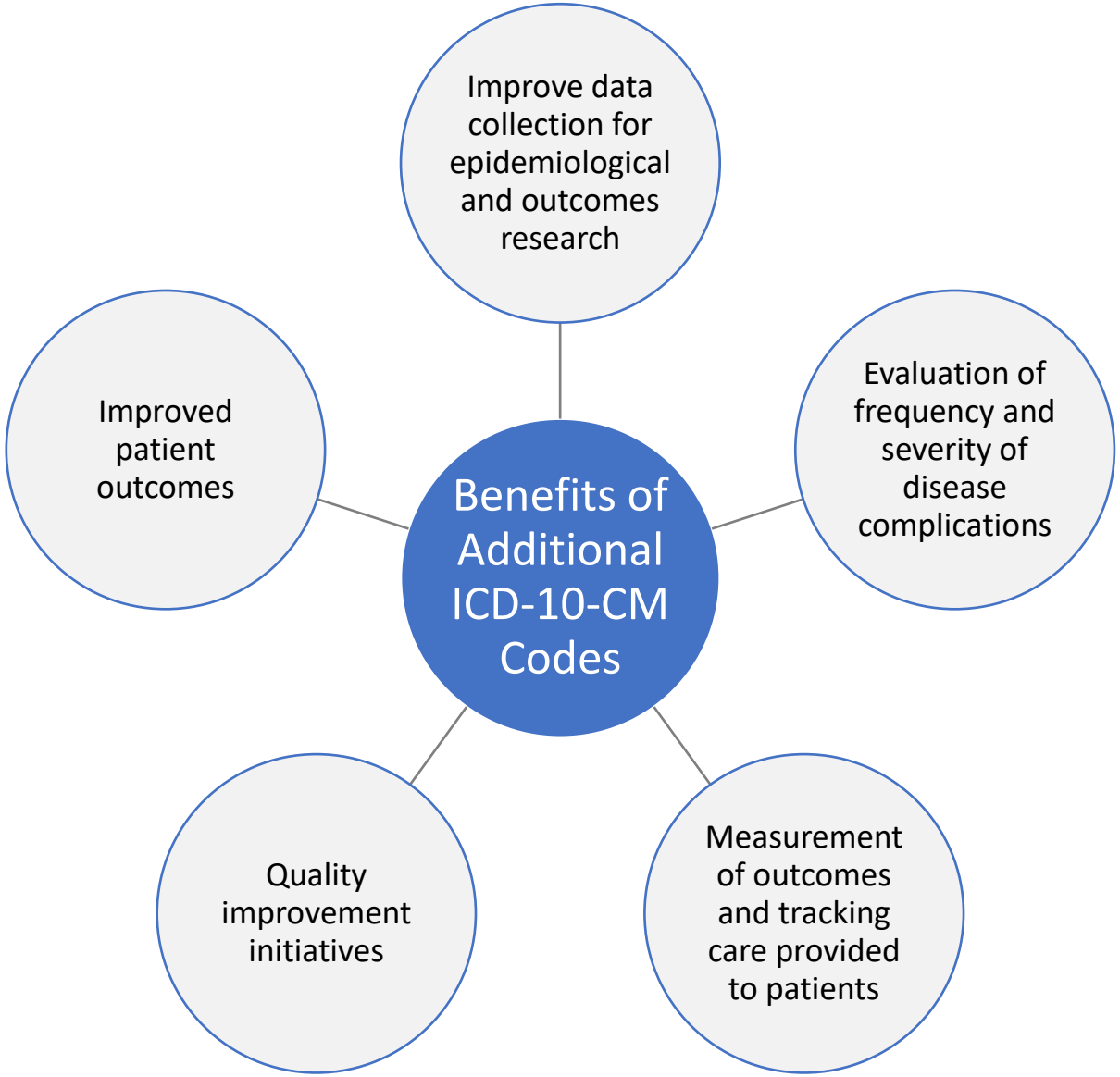
- Despite differences in outcomes and treatment paradigms, current ICD-10-CM Coding, K60.3 Anal Fistula, does not differentiate between simple versus complex fistulas, nor does it distinguish between unspecified, persistent, and recurrent fistulas
- Creation of unique ICD-10-CM codes to differentiate between unspecified, persistent, and recurrent as well as simple vs. complex fistulas could advance patient care and long-term health outcomes through improved tracking and research