Acute Flaccid Myelitis

Sarah Kidd, MD MPH
Medical Officer
AFM and Domestic Poliovirus Team
Division of Viral Diseases
Centers for Disease Control and Prevention

ICD-10 Coordination and Maintenance Committee Meeting

September 9, 2020

Conflict of interest and disclosures

Dr. Kidd has no conflicts of interest to disclose.

Acute flaccid myelitis (AFM)

- The term was created in 2014 to describe illness in patients with sudden onset of limb weakness and lesions in the spinal cord gray matter
- Clinical presentation is similar to poliomyelitis
- Mostly children are affected
- Viral causes:
  - non-polio enteroviruses (EV-D68, EV-A71)
  - flaviviruses (West Nile virus, Japanese encephalitis virus)
  - herpesviruses
  - adenoviruses

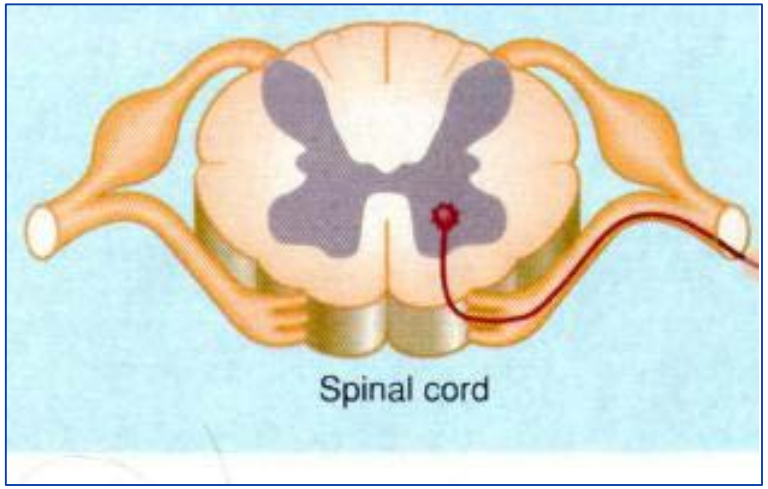

Caption: Cross-section of the spinal cord showing the gray matter and lower motor neurons affected in AFM.

National increase in AFM cases every 2 years since 2014

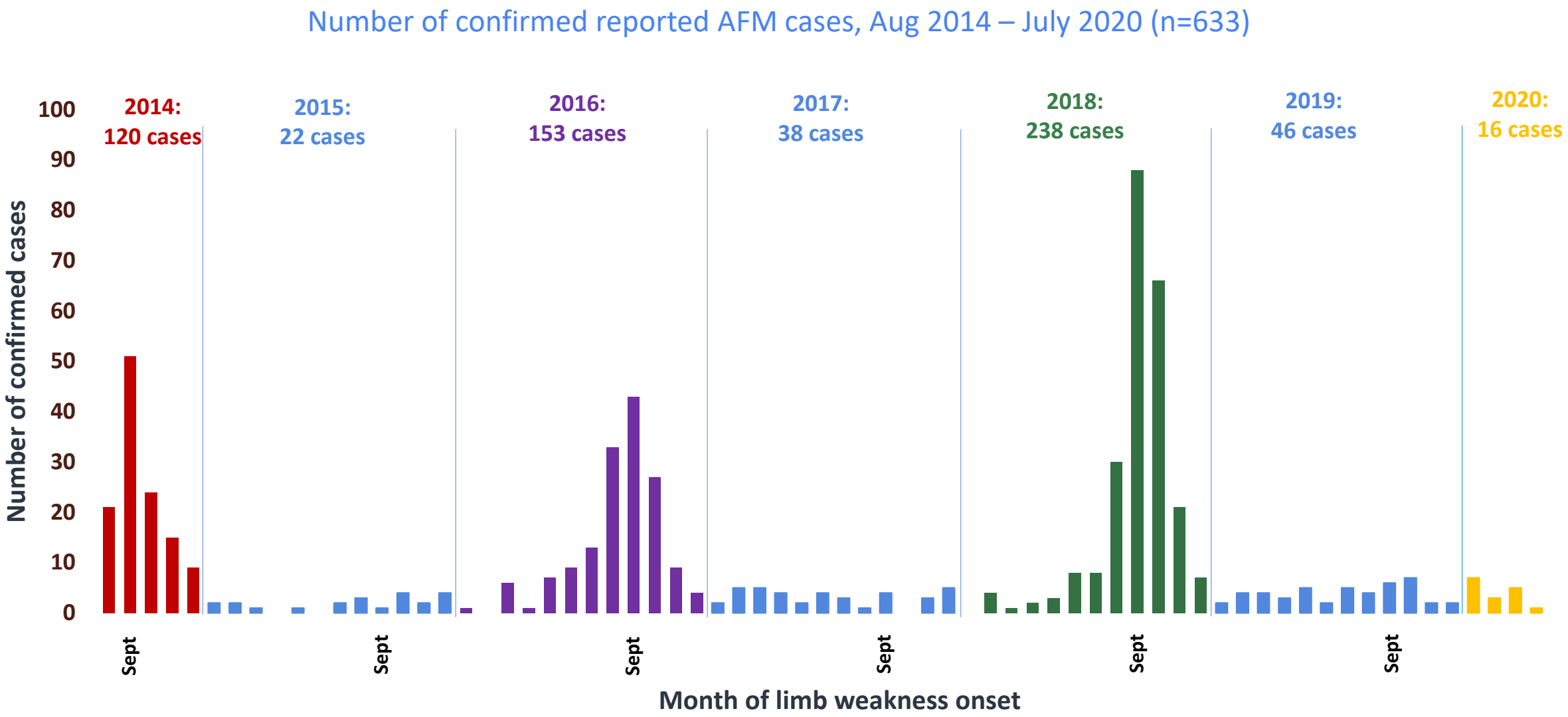

https://www.cdc.gov/acute-flaccid-myelitis/cases-in-us.html Data current as of July 31, 2020.

U.S. surveillance shows a consistent baseline rate of AFM

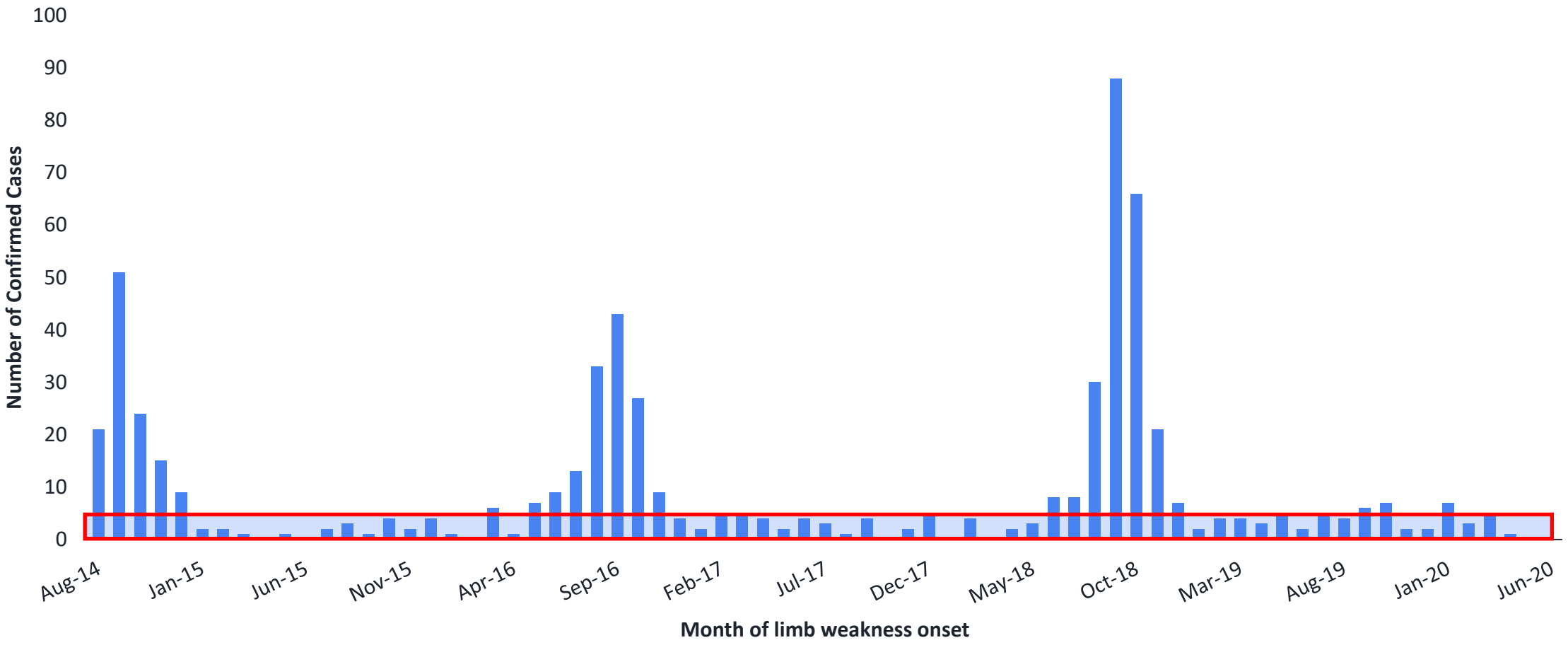

https://www.cdc.gov/acute-flaccid-myelitis/cases-in-us.html

What is causing the biennial peaks in AFM?

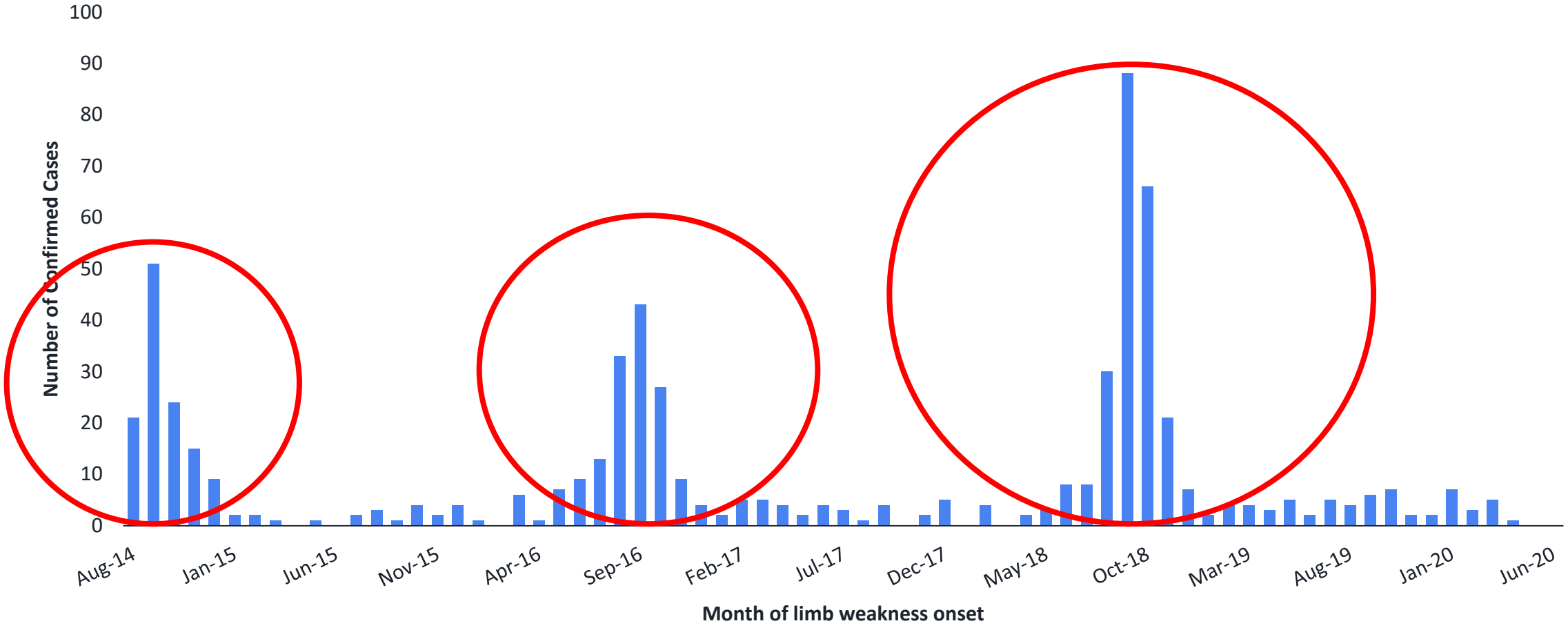

https://www.cdc.gov/acute-flaccid-myelitis/cases-in-us.html

Temporal association between AFM and EV-D68 in the United States, 2014

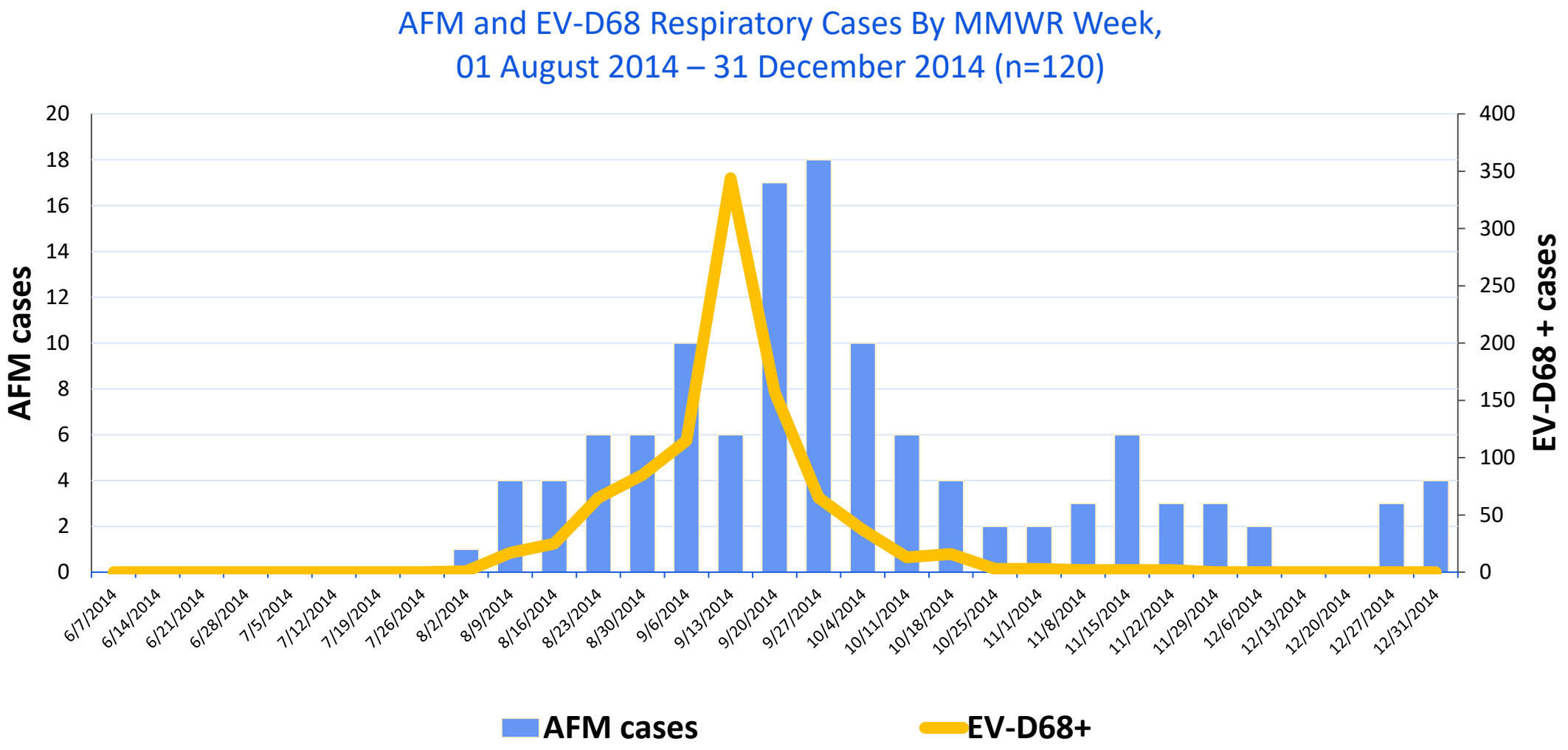

Sejvar J, et al. Acute Flaccid Myelitis in the US, 2014, CID, 2016

AFM diagnostic testing remains low yield

CDC testing results, 2018

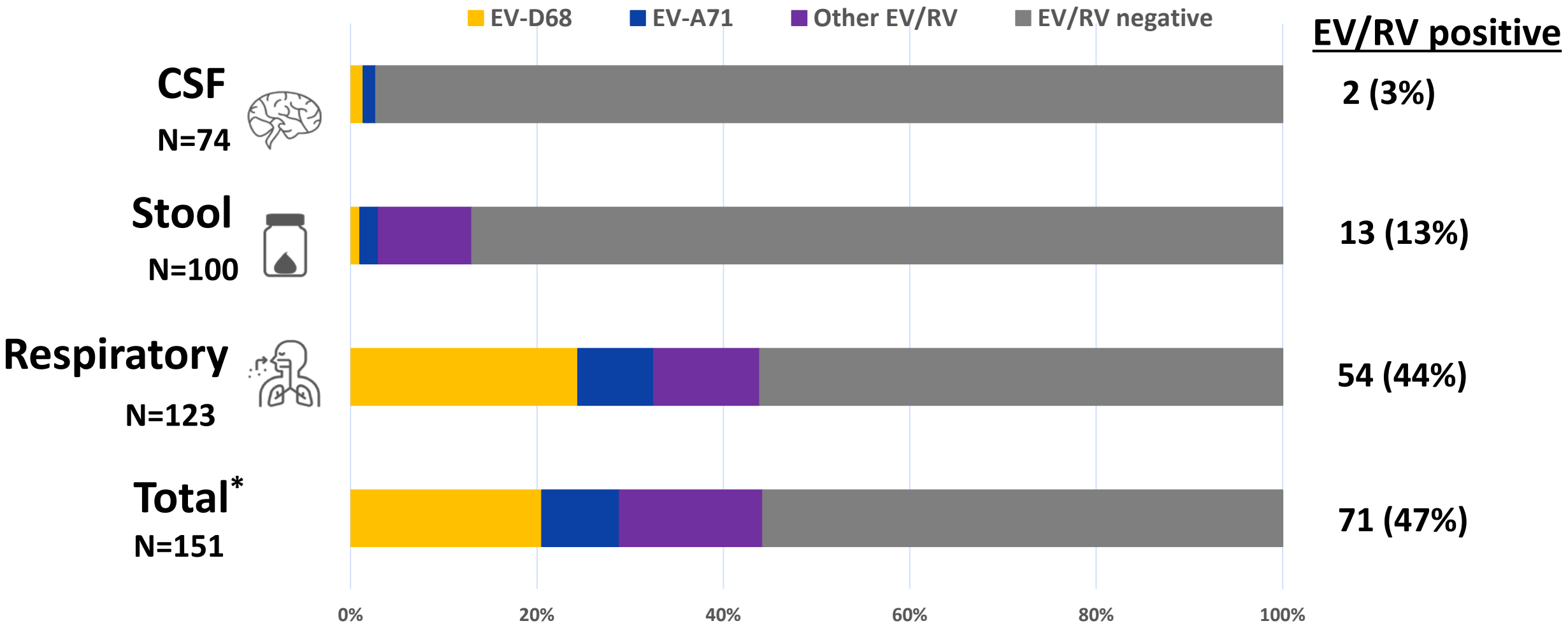

*Some patients had multiple positive specimens

Lopez, et al. Vital Signs: Surveillance for Acute Flaccid Myelitis – US, 2018, MMWR 2019

Further evidence for role of enteroviruses in AFM

AMERICAN SOCIETY FOR MICROBIOLOGY | mBio®

RESEARCH ARTICLE
Clinical Science and Epidemiology

Antibodies to Enteroviruses in Cerebrospinal Fluid of Patients with Acute Flaccid Myelitis

Nischay Mishra,[a] Terry Fei Fan Ng,[b] Rachel L. Marine,[b] Komal Jain,[a] James Ng,[a] Riddhi Thakkar,[a] Adrian Caciula,[a] Adam Price,[a] Joel A. Garcia,[a] Jane C. Burns,[c] Kiran T. Thakur,[d] Kimbell L. Hetzler,[e] Janell A. Routh,[b] Jennifer L. Konopka-Anstadt,[b] W. Allan Nix,[b] Rafal Tokarz,[a] Thomas Briese,[a] M. Steven Oberste,[b] W. Ian Lipkin[a]

nature medicine

LETTERS
https://doi.org/10.1038/s41591-019-0613-1

Pan-viral serology implicates enteroviruses in acute flaccid myelitis

Ryan D. Schubert[1,2], Isobel A. Hawes[1,2,18], Prashanth S. Ramachandran[1,2,18], Akshaya Ramesh[1,2,18], Emily D. Crawford[3,4], John E. Pak[3], Wesley Wu[3], Carly K. Cheung[3], Brian D. O'Donovan[5], Cristina M. Tato[3], Amy Lyden[3], Michelle Tan[3], Rene Sit[3], Gavin A. Sowa[6], Hannah A. Sample[5],

- Both studies found that AFM cases had higher levels of enterovirus-specific antibodies in CSF compared with non-AFM controls
- Results are supportive of the leading hypothesis that enterovirus infection plays a key role in development of AFM

AFM clinical presentation

- Most patients had preceding febrile illness 1-2 weeks before the **sudden onset of flaccid limb weakness**
  - Frequently respiratory or gastrointestinal illness with symptoms of fever, rhinorrhea, cough, vomiting or diarrhea
- Onset of weakness is rapid
  - Within hours to a few days
- Weakness is in one or more limbs
  - More proximal than distal
- Loss of muscle tone and reflexes

https://www.cdc.gov/acute-flaccid-myelitis/symptoms.html

AFM clinical presentation (2)

- Cranial nerve abnormalities may be present
  - Facial or eyelid droop
  - Difficulty swallowing or speaking
  - Hoarse or weak cry
- Some patients may complain about stiff neck, headache, or pain in the affected limb(s)
- Uncommonly, people may also:
  - Have numbness or tingling in the arms or legs

https://www.cdc.gov/acute-flaccid-myelitis/symptoms.html

AFM clinical presentation (3)

- The most severe complications of AFM are:
  - **Respiratory failure,** requiring mechanical ventilation
  - **Serious neurologic manifestations** such as body temperature changes and blood pressure instability that could be life threatening

Clinicians should immediately admit patients to the hospital because AFM can progress rapidly and require urgent medical intervention, like assistance with breathing.

https://www.cdc.gov/acute-flaccid-myelitis/symptoms.html

Differential diagnosis of flaccid limb weakness

AFM may resemble:

- Synovitis
- Neuritis
- Limb injury
- Guillain-Barre syndrome (GBS)
- Transverse myelitis
- Stroke, including spinal stroke
- Tumor
- Acute cord compression
- Conversion disorder

- AFM must be high on differential diagnosis in **late summer or early fall**, especially in patients with preceding viral symptoms.
- Careful neurological examination, laboratory testing, and MRI of the spine and brain can help guide diagnosis

Murphy O, Pardo C. AFM: A Clinical Review. *Semin Neurology*. 2020 April; 40(2): 211-218.; Hardy D, Hopkins SE. Update on AFM: Recognition, reporting, aetiology, and outcomes. *Arch Dis Child*. 2020 Feb 10. DOI:: 10.1136/archdischild-2019-316817; Hopkins SE, Elrick MJ, Messacar K. Acute Flaccid Myelitis – Keys to Diagnosis, Questions About Treatment, and Future Directions. *JAMA Pediatrics.* 2018. Nov 30. DOI: 10.1001/jamapediatrics.2018.4896.

Initial neurodiagnostic studies

- Laboratory Tests
  - Cerebrospinal fluid (CSF)
    - cell count with differential, protein and glucose; oligoclonal bands; meningitis/encephalitis PCR panel
  - Serum
    - EV PCR, anti-MOG (myelin oligodendrocyte glycoprotein) and anti-aquaporin antibodies, HSV, EBV, WNV
  - Stool/Rectal swab for EV PCR
  - Nasopharyngeal (NP) and/or oropharyngeal (OP) swabs
    - respiratory multiplex testing and enterovirus (EV) PCR
- Neuroimaging
  - MRI of the spine and brain
- Consider additional pathogen-specific testing (e.g., Lyme) based on seasonality, exposures, and geography

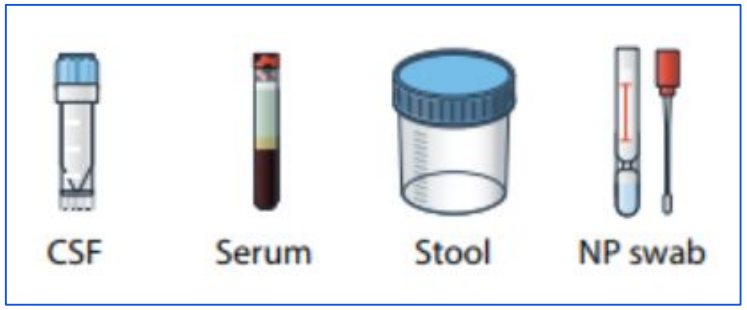

Note: Some of these studies may require sedation, depending on child's age

- Coordinate the procedures to avoid repetitive sedation if possible
- Monitor respiratory status continuously

Hardy D, Hopkins SE. Update on AFM: Recognition, reporting, aetiology, and outcomes. *Arch Dis Child*. 2020 Feb 10. DOI:: 10.1136/archdischild-2019-316817

Characteristic MRI findings in AFM

- A, B. Sagittal and axial images demonstrating hyperintensity of the entire central gray matter of the thoracic spinal cord; on axial imaging, demonstrating characteristic ‘H’ shape pattern.

- D, E. Sagittal and axial images demonstrating T2 hyperintensity confined to the left anterior horn cells (best demonstrated in E)

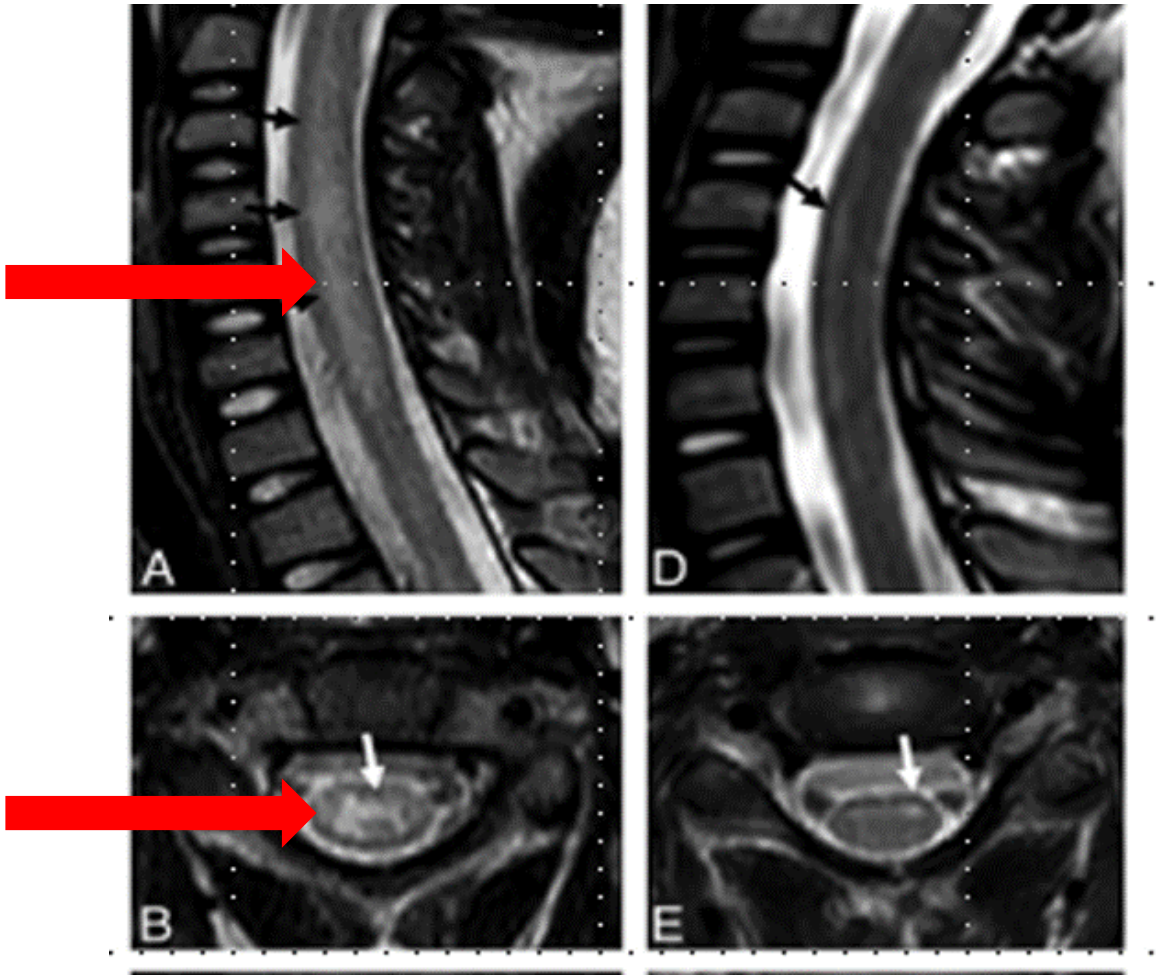

From: Maloney JA et al. *Am J Neuroradiol* 2015;36(2):245-50.

Medical treatments for AFM

- Treatments commonly used for AFM in the acute phase include:
  - Intravenous immunoglobulin (IVIG)
  - Corticosteroids
  - Plasmapheresis
- There is not enough human evidence to indicate a preference or an avoidance for their use at this time
  - Treatment decisions should be made in conjunction with neurology and infectious disease experts
  - Potential benefits of using corticosteroids for spinal cord edema or white matter involvement must be balanced by potential harm due to immunosuppression in the setting of a possible viral infection
  - There is no indication for the use of fluoxetine, antiviral, and/or other immunosuppressive agents for AFM

Clinical Outcomes

- Spectrum of disease and outcomes
- Estimated ~90% of patients have residual deficit
- Long-term: muscle atrophy, orthopedic complications
- Many require assistive devices for mobility
- Some require ongoing ventilatory support

- Early initiation of rehabilitation seems to optimize recovery
- Patients can continue to make gains with prolonged rehabilitation services

Summary

- AFM is a serious neurologic condition characterized by flaccid limb weakness/ paralysis and selective inflammation of the central gray matter of the spinal cord
- The epidemiology of AFM appears to have changed recently
  - Increased cases every 2 years in the United States since 2014
  - Suggests new or emerging infectious etiology
- A specific ICD-10 code would enhance ability to detect/monitor trends in AFM and facilitate characterization of AFM, including etiologies, management, treatment, and outcomes

For more information, contact CDC
1-800-CDC-INFO (232-4636)
TTY: 1-888-232-6348 www.cdc.gov

The findings and conclusions in this report are those of the authors and do not necessarily represent the official position of the Centers for Disease Control and Prevention.

Photographs and images included in this presentation are licensed solely for CDC/NCIRD online and presentation use. No rights are implied or extended for use in printing or any use by other CDC CIOs or any external audiences.