Central Centrifugal Cicatricial Alopecia

ICD-10 Coordination and Maintenance March 2023 Meeting

Speaker: Dr. Amy McMichael, MD



Itisha S. Jefferson

Morinola Shobajo

Jessica Brown-Korsah

James Pathoulas, MD

Maria Hordinsky, MD

Amy McMichael, MD

SAF scarring alopecia.org
SCARRING ALOPECIA FOUNDATION

AAD American Academy of Dermatology Association

DISCLOSURE/CONFLICTS OF INTEREST

Investigator

Allergan

Procter & Gamble

Concert

Incyte

Consultant

Johnson & Johnson

Procter & Gamble

Allergan

UCB

Galderma

Incyte

Eli Lilly

Aclaris

Pfizer

Arcutis

Allmirall

Overview of Central Centrifugal Cicatricial Alopecia (CCCA)

- **CCCA** is a rare type of scarring alopecia that manifests clinically as patches of permanent hair loss on the vertex or crown of the scalp and spreads centrifugally.
- This type of hair loss is associated with **inflammation**-related signs and symptoms
  - Itching, burning, redness, pain
- It is a condition that affects women of African descent and runs in families (often inherited in an autosomal dominant manner).
- Topical and intralesional steroids along with oral tetracyclines are the treatment of choice. However, these therapies often result in **minimal response**.
- Patients experience **decreased quality of life and psychosocial distress** from disfigurement and scalp symptoms

SAF

Figure 1. A 16-year-old girl (patient 1) with patchy hair loss involving the left and right parietal scalp.

FIGURE 1 Spectrum of CCCA disease severities: Patients with stage 1B (focal, (A)), stage 3B (limited, (B)) and stage 5B (extensive, (C)) disease

Epidemiology

- Central centrifugal cicatricial alopecia (CCCA) predominantly affects women of African descent.
- The true prevalence of CCCA remains unknown due to minimal population studies; some studies show a prevalence from 2.7% to 5.6%.
- CCCA is less common among adolescents and children. However, this may be due to delayed diagnosis or misdiagnosis.

SAF

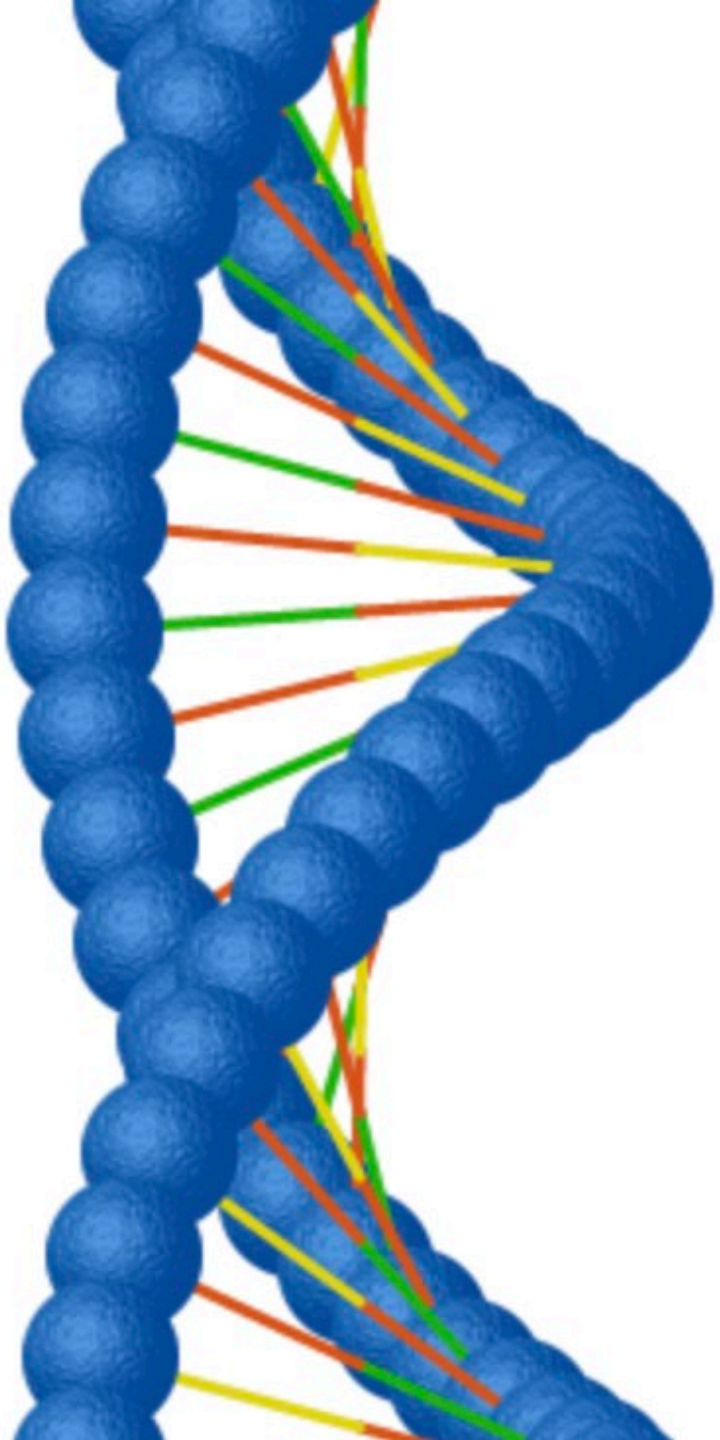

Emerging Evidence in the Genetic Composition of CCCA

- Autosomal dominant mode of inheritance with varying degrees of penetrance.
- *Malki L, Sarig O, Romano MT, et al* study showed that approximately 24% (14 out of 58) patients with CCCA had a variant of PADI3 (peptidylarginine deiminase III).
- PADI3 encodes for the protein that is essential for proper hair-shaft formation.
- Variants of PADI3 were found to result in reduced PADI3 expression, abnormal intracellular localization of the protein, and decreased enzymatic activity.
- Biallelic PADI3 mutations have been implicated in patients with uncombable hair syndrome

SAF

Clinical Features

- CCCA presents with scarring at the vertex or crown of the scalp that tends to spread centrifugally.
- Symptoms may include itchy, tender scalp; seborrheic-type scale, follicular papules; and
- pustules to completely asymptomatic hair breakage at the vertex of the scalp.
- Some patients can be asymptomatic.

- **Olsen Scale shows the gradations in hair loss from normal (0) to bald scalp (5)**

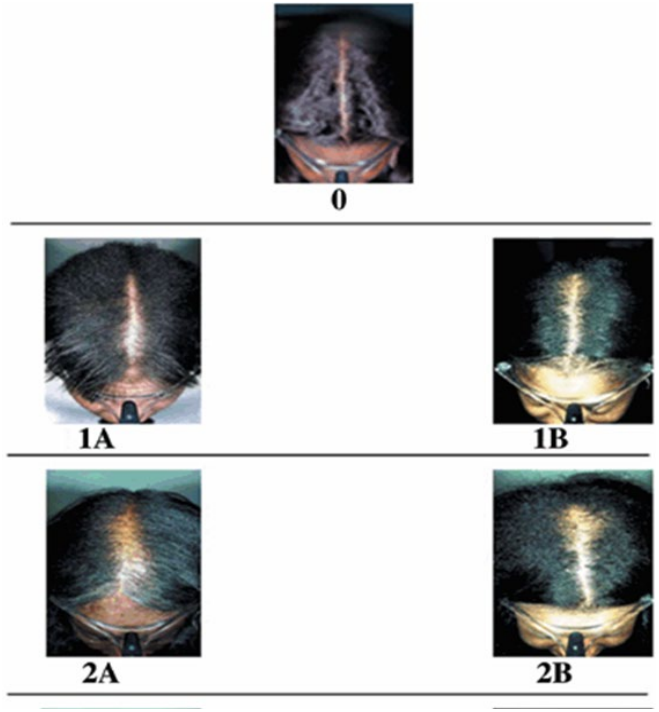

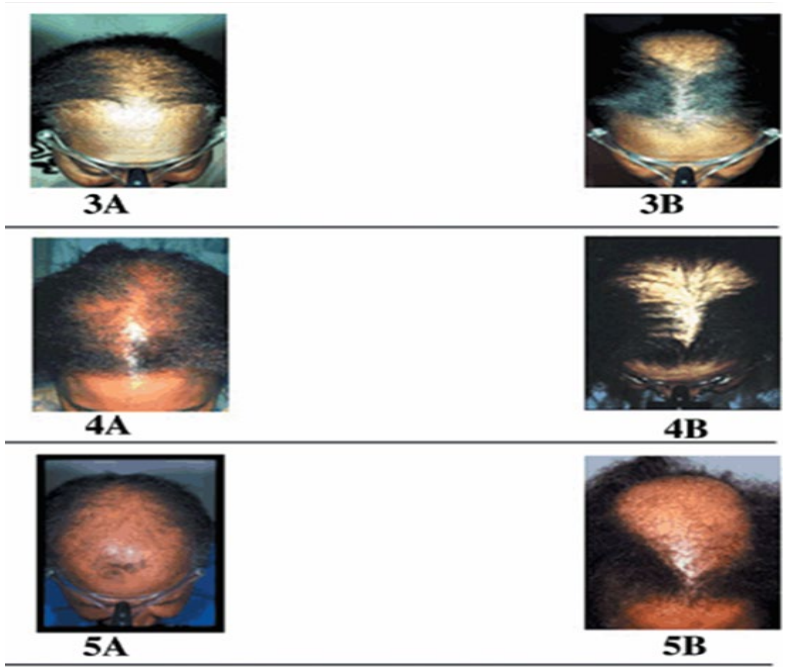

Diagnosis

Clinically

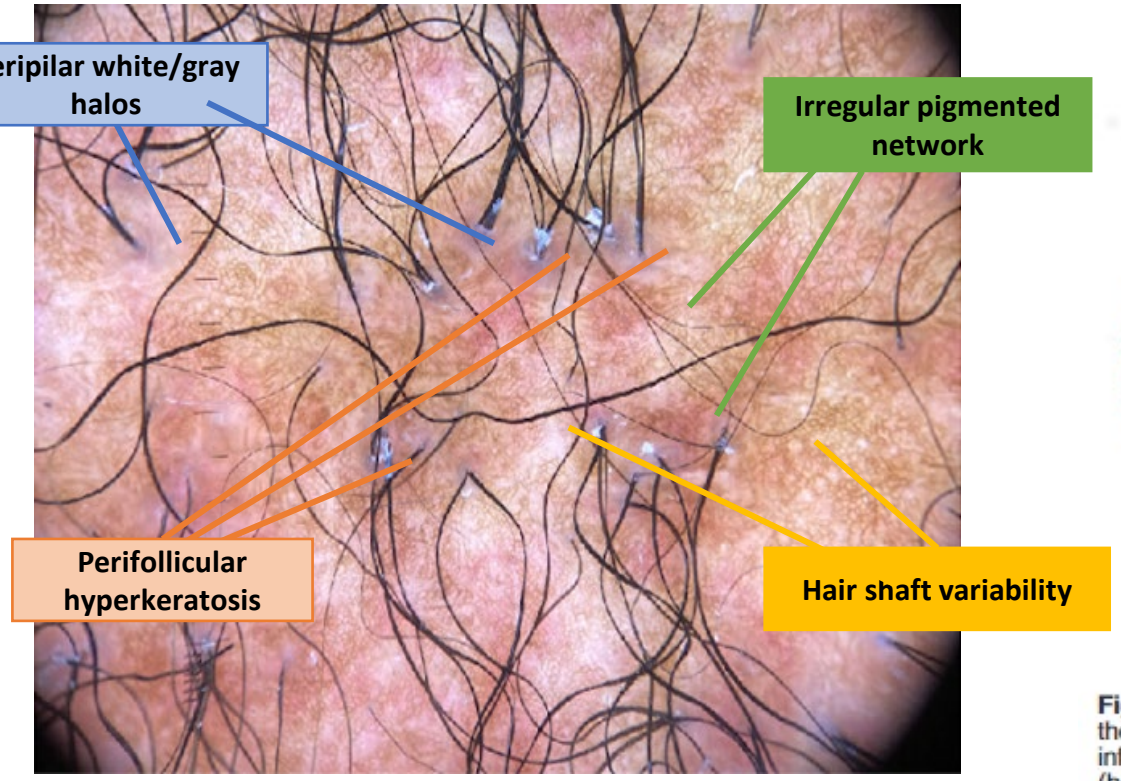

Trichoscopy

Figure 4. Histopathology of patient 1. Biopsy specimen of the vertex scalp shows focally dense bandlike perifollicular infiltrate at the level of the infundibulum and isthmus (hematoxylin and eosin, 10×).

Histopathology

Treatment

- **Since CCCA is a permanent form of hair loss, initiating treatment in the early stages of disease is critically important.**

- **Current treatment has a two-pronged approach**:
  1) Reduce inflammation
  2) Slow the progression of disease

- **Treatments include:**
  1) Topical steroids
  2) Intralesional corticosteroids
  3) Oral tetracyclines
  4) Hydroxychloroquine

****Limited efficacy of current therapies and dearth of clinical research trials can lead to further progression of hair loss and can have a negative impact of the quality of life of CCCA patients.****

SAF

Current ICD-10-CM Codes

- Disorders of skin appendages (L60-L75)
  - Cicatricial alopecia (L66)
    - Pseudopelade(L66.0)
    - Lichen planopilaris (L66.1)
    - Folliculitis decalvans (L66.2)
    - Perifolliculitis capitis abscedens (L66.3)
    - Folliculitis ulerythematosa reticulata(L66.4)
    - **Other cicatricial alopecia (L66.8)**
    - **Cicatricial alopecia, unspecified (L66.9)**

Rationale For A Stand-Alone ICD-10-CM Code for CCCA

The current ICD-10-CM coding for CCCA does not adequately capture the current and ongoing clinical understanding of CCCA.

A specific ICD-10-CM code for CCCA would be a momentous step forward for the study of ***this unique disease*** as improved coding granularity would:

- ✓ Better track disease prevalence and contribute to health policy decision-making
- ✓ Evaluate symptom progression of CCCA and any associated co-morbidities
- ✓ Monitor adherence to clinical management guidelines
- ✓ Track and improve patient-related care outcomes
- ✓ Greater epidemiologic monitoring with greater access to Electronic Medical Records and other large Real World Evidence datasets and databases
- ✓ Improved retrospective studies comparing best treatment and management practices and encouragement of pharmaceutical research, clinical trials and patient registries
- ✓ Improved patient care access and quality improvement initiatives

SAF

Support


AMERICAN ACADEMY OF DERMATOLOGY
AAD
1938

SAF
scarring alopecia.org
SCARRING ALOPECIA FOUNDATION

References

1. Aguh C, McMichael A. Central Centrifugal Cicatricial Alopecia. JAMA Dermatol. 2020;156(9):1036. doi:10.1001/jamadermatol.2020.1859
2. Dlova NC, Salkey KS, Callender VD, McMichael AJ. Central centrifugal cicatricial alopecia: new insights and a call for action. J Investig Dermatol Symp Proc 2017;18:S54-S56.
3. McMichael A, Hordinsky M. Hair and Scalp Disorders Medical, Surgical, and Cosmetic Treatments, Second Edition. 2nd ed. CRC Press; 2018.
4. Olsen EA, Callender V, Sperling L, et al. Central scalp alopecia photographic scale in African American women. Dermatol Ther. 2008;21(4):264-267. doi:10.1111/j.1529-8019.2008.00208.x
5. Malki L, Sarig O, Romano MT, et al. Variant PADI3 in Central Centrifugal Cicatricial Alopecia. N Engl J Med. 2019;380(9):833-841. doi:10.1056/NEJMoa1816614
6. Maranga A, Roche FC, Alausa M, et al. Quality of life in patients with central centrifugal cicatricial alopecia: a preliminary study. Br J Dermatol. 2022;187(5):802-804. doi:10.1111/bjd.21710
7. Ogunleye TA, McMichael A, Olsen EA. Central centrifugal cicatricial alopecia: what has been achieved, current clues for future research. Dermatol Clin. 2014;32(2):173-181. doi:10.1016/j.det.2013.12.005
8. Dlova NC, Jordaan FH, Sarig O, Sprecher E. Autosomal dominant inheritance of central centrifugal cicatricial alopecia in black South Africans. J Am Acad Dermatol 2014;70(4):679-682.e1.
9. Flamm A, Moshiri AS, Roche F, Onyekaba G, Nguyen J, James AJ, Taylor S, Seykora JT. Characterization of the inflammatory features of central centrifugal cicatricial alopecia. J Cutan Pathol. 2020 Jun;47(6):530-534
10. Eginli AN, Dlova NC, McMichael A. Central Centrifugal Cicatricial Alopecia in Children: A Case Series and Review of the Literature. Pediatr Dermatol. 2017;34(2):133-137. doi:10.1111/pde.13046
11. Gabros, S., & Masood, S. (2022). Central Centrifugal Cicatricial Alopecia. In *StatPearls*. StatPearls Publishing.
12. Jamerson TA, Conover Talbot C, Dina Y, Kwatra SG, Garza LA, Aguh C. Gene expression profiling suggests severe, extensive central centrifugal cicatricial alopecia may be both clinically and biologically distinct from limited disease subtypes. Experimental Dermatology. 2022;31(5):789-793. doi:10.1111/exd.14524
13. McKenzie SA, Roche FC, Onyekaba G, Williams DM, Ogunleye TA, Taylor SC. Comorbid anxiety and depression among black women with central centrifugal cicatricial alopecia: A retrospective study. Journal of Dermatology. 2021;48(1):e19. doi:10.1111/1346-8138.15595

SAF