The Agency for Healthcare Research and Quality (AHRQ) is Requesting New ICD-10-CM Codes Specific for:

- Cement Embolism of Pulmonary Arteries
- Fat Embolism of Pulmonary Arteries

Presented by Dr. Richard H. White, Professor of Medicine, UC Davis, on behalf of AHRQ

Representing: UC Davis AHRQ Patient Safety Team Members: Patrick S Romano MD, Garth H Utter MD, and John W. Kennedy, Clinical Documentation Specialist.

Pulmonary Embolism

- To most physicians, the term ‘pulmonary embolism’ (PE) means a blood clot has entered the pulmonary circulation.

- These emboli are blood clots (thrombi), usually treated by systemic anticoagulation therapy.

Fat Embolism

- Fat embolism is when one or more droplet-like particles of fat enter the bloodstream and embolize to the systemic or pulmonary circulation.

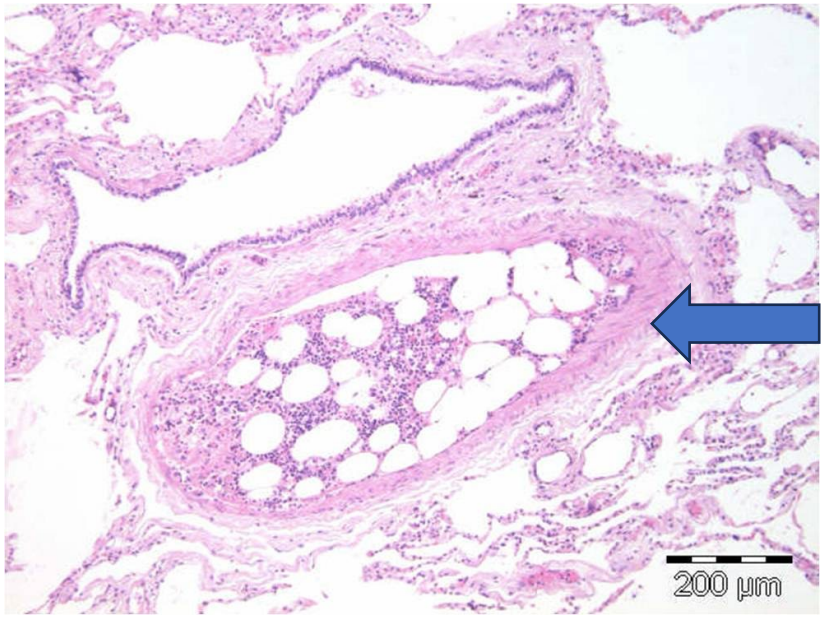

Tissue section showing fat embolism in a pulmonary artery.

Most Frequent Causes of Fat Embolism:

- Following long bone and pelvic fractures.
- Following orthopedic surgeries such as total hip or knee arthroplasties.

Treatment of Pulmonary Fat Embolism

- Supportive care: which can include fluid resuscitation, oxygenation, and when indicated, noninvasive or invasive mechanical ventilation.
- Fat embolism is not treated with systemic anticoagulation.

Pulmonary Cement Embolism is:

- Iatrogenic form of PE resulting from the use of PolyMethyl MethAcrylate (PMMA) during orthopedic procedures, such as:
- Vertebroplasty/Kyphoplasty
- Hip and knee arthroplasty

CT images without contrast showing cement emboli in the lung. The cement appears white.

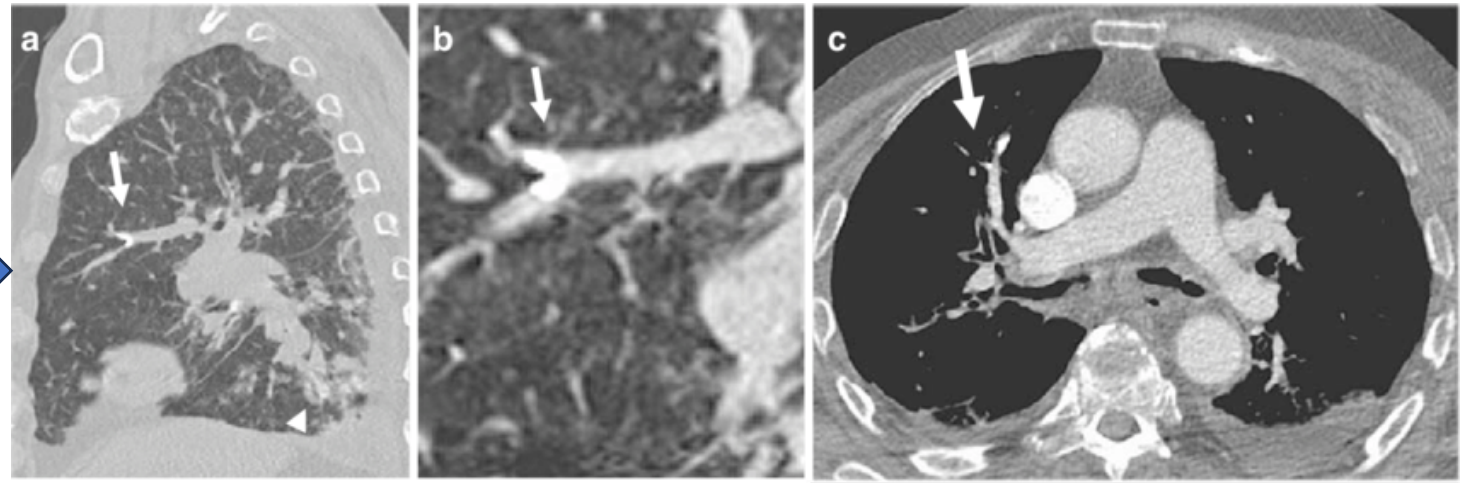

Pulmonary Cement Embolism

May occur during vertebroplasty or kyphoplasty, or following hip or knee arthroplasty when PMMA leaks into the venous circulation, subsequently hardening in the pulmonary vasculature.

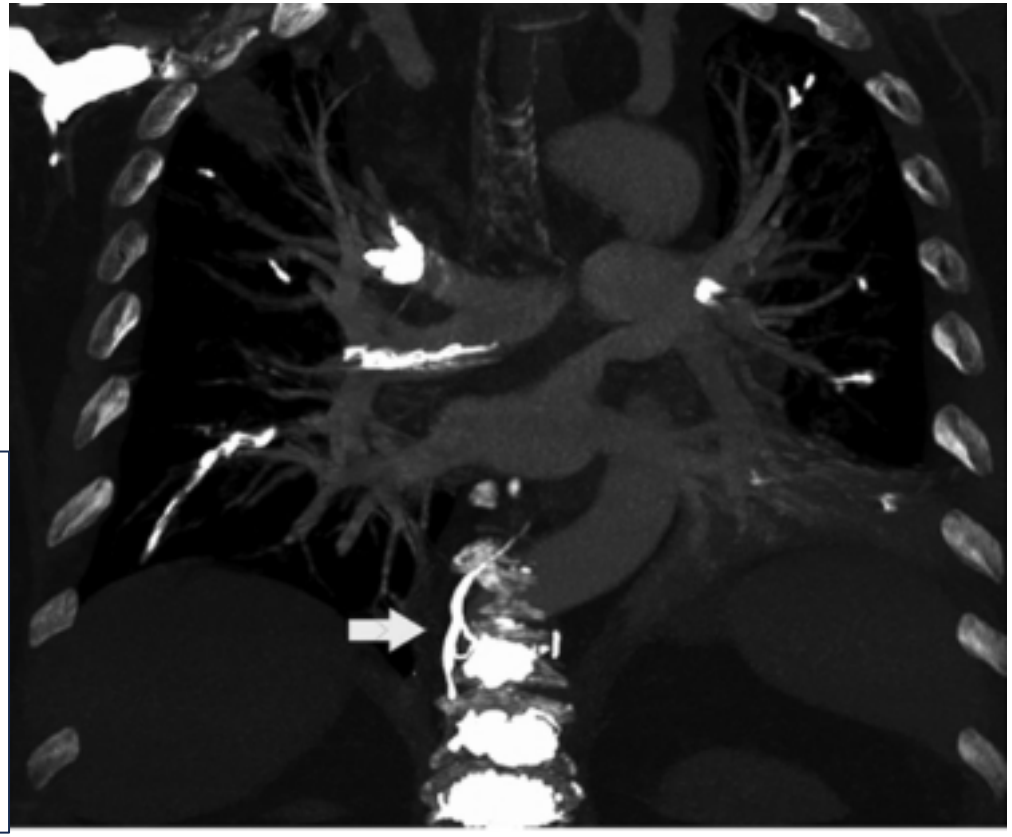

Coronal reconstruction showing bilateral cement Emboli in the lung, and leakage of cement into the right paravertebral venous system following vertebroplasty (arrow).

Pulmonary Cement Embolism is cont.:

- Mechanical occlusion of pulmonary arteries.
  => Cement Emboli are not blood clots!

Treatment of Pulmonary Cement Embolism:

- Treatment of a pulmonary embolism caused by cement emboli is entirely different than treatment of a blood clot embolism to the lung.
- It is not treated with systemic anticoagulation.
- Treatments include embolectomy, supportive care and observation.

Conclusion

There is a need to create new ICD-10-CM codes specific for: 1) fat pulmonary embolism
2) cement pulmonary embolism
each with and without acute cor pulmonale; such coding will create specificity for epidemiologic research, tracking, and trending.

Thank You

REFERENCES:

Rothberg DL, Makarewich CA. *Fat Embolism and Fat Embolism Syndrome*.
J Am Acad Orthop Surg. 2019 Apr 15;27(8):e346-e355. doi: 10.5435/JAAOS-D-17-00571. PMID: 30958807.

Sun X, Deng M, Xu W, et al. *Features and risk factors of pulmonary cement embolism after vertebroplasty or kyphoplasty in patients with vertebral compression fracture: a retrospective cohort study.*
Quant Imaging Med Surg. 2023 Apr 1;13(4):2397-2407. doi: 10.21037/qims-22-569. PMID: 37064367; PMCID: PMC10102772.